

# History

- A 30-year-old male presents with a phthisical left eye and undergoes enucleation. He has some lesions in his right eye that are under ophthalmic surveillance.
- Figure 1 is a low power of the enucleation.
- Figures 2, 3 and 4 are higher power shots of the arrowed lesion in Figure 1.

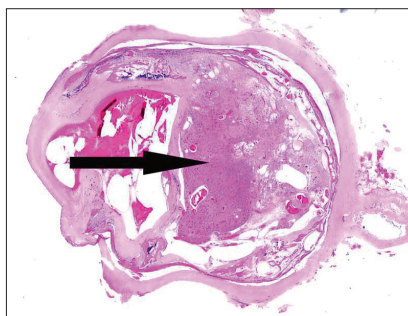


Figure 1

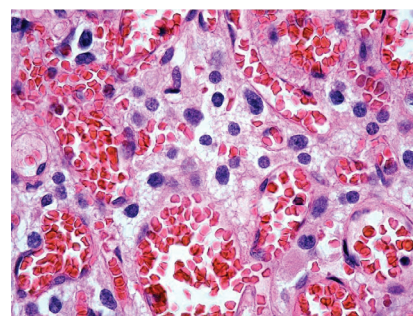


Figure 3

# Questions

1. What do Figures 2 and 3 show?
2. What does Figure 4 show (arrow)?
3. What is the likeliest diagnosis?
4. Which immuno-stain will highlight the cells in Figure 4?
5. What other history may you ask for from the clinicians?

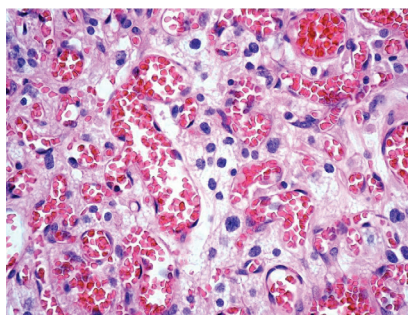


Figure 2

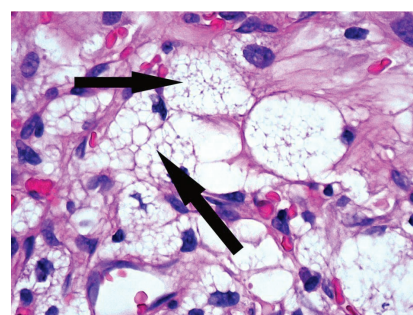


Figure 4

- Other organs: cysts.
  - Adnexae: cystadenoma
  - Epididymis: epididymal cystadenoma
  - Endolymphatic sac / duct: endolymphatic sac tumour
  - Adrenal gland / paraganglia: pheochromocytoma / paraganglioma
  - Pancreas: cysts, microcystic adenoma and neuroendocrine tumours
  - Kidney: cysts and renal cell carcinoma
  - Peripheral nerves: haemangioblastoma
  - Retina: haemangioblastoma
- The systemic manifestations are:
5. This patient has Von Hippel Lindau disease (hence the lesions in the other eye).
  4. Anti-VEGF.
  3. The combination of endothelial and foamy stromal cells makes this a retinal haemangioblastoma. The stromal cells are the neoplastic element.
  2. Foamy stromal cells between the vascular element.
  1. A vascular neoplasm.

# Answers

## Further reading

- <http://emedicine.medscape.com/article/1219430-overview>
- WHO classification of tumours of the central nervous system. Third edition. IARC Press; 2007:215-7.
- Mettu P, Agron E, Samtani S, et al. Genotype-phenotype correlation in ocular von Hippel-Lindau (VHL) disease: The effect of missense mutation position on ocular VHL phenotype. *Invest Ophthalmol Vis Sci* 2010;**51**(9):4464-70.

## AUTHOR

### Dr Hardeep Singh Mudhar,

Ophthalmic Histopathologist,  
National Specialist Ophthalmic Pathology Service,  
Dept of Histopathology, Royal Hallamshire Hospital,  
Sheffield, UK.