

Sensitive cilia – eyelashes in health and disease

BY RACHNA MURTHY AND JONATHAN ROOS

In health our eyelashes protect the eyes, but in disease they can disfigure, impair quality of life and threaten vision. In this review the authors discuss aspects of lashes that are relevant to all professionals working near the eyes and how to keep you and your patients safe.

Our eyelashes frame the eyes and are a key facial aesthetic: we have evolved to be preoccupied by the periocular area when we meet someone. Eye tracking studies show that our gaze is primarily focussed on the eyes and periocular area when looking at one another [1]. When we look into someone's eyes we feel we can see their soul – but except for pupil size the eye itself does not change – rather it is the surrounding tissues which speak to us.

The eyelashes contribute significantly to this aesthetic and communication; whole industries have been spawned for their enhancement. Early eyeliners contained a variety of materials including copper ore, kohl and antimony [2], were smeared to give more expression to the eyes, protect from the desert sun or for magical reasons protecting the wearer from the 'evil-eye' and are recorded in discoveries from 3500 BC. This practice also had medicinal purposes: galena, a component of the eye cosmetic, is an effective insect repellent and disinfectant [3].

In the 19th century, chemist Eugene Rimmel developed the product that we would recognise as mascara today using a newly invented petroleum jelly mixed with coal. Although petroleum jelly can be used on lashes, it renders the application quite messy and should not be used in the eye, however, the benefits of petroleum and its mineral oils continue to this day for medicinal purposes, as a major constituent of many topical treatments for dry eye disease (DED), resulting from decades of lash pathology and blepharitis [4].

Lashes for health

The human eyelid has 75-80 lashes (cilia) in three to four rows in the lower eyelid and 90-160 scattered in five to six rows in the upper lid [5]. They are an integral part of the eyelid margin anatomy, and serve to protect our eyes. Highly innervated and sensitive to objects or the wind, they rapidly trigger the blink reflex [6].

Eyelash formation starts around week 12 of gestation while the eyelids are still fused, and are the first hairs to grow. After their development by the 26th week they become aligned and firmly embedded into the eyelid margin [7]. They grow in imperfect rows along the front edge of the eyelid providing a filamentous curtain-like projection that is designed to leave no area of the cornea unprotected [8]. Unlike other hair in the body, eyelash follicles do not have an arrector pili muscle, so cannot stand up without mechanical help, but their curvature away from the cornea ensures that the upper and lower lashes do not intertwine with every blink [9]. Ethnic variations exist, for example, eyelashes from East Asian females show a reduced curl angle, an increased hair shaft diameter and more hair cuticle layers compared with eyelashes from Caucasian females [10]. Each eyelash consists of an inner medulla of loose cells, a surrounding thicker cortex composed

of the protein keratin also containing melanin and an outermost impermeable cuticle of several layers of scale-like cells. They are coated with sebum secreted by a gland named after Dr Zeis (Figure 1). Like all hair, lashes transition through three phases in their life but with a short anagen growth phase and long resting telogen phase (Figure 2). This means that they reach no more than around 10mm before growth stops. They then shed naturally after a few months. One to four lashes are lost per day. Eyelashes tend to be the darkest hairs in the body and the last ones to undergo greying, usually late in life [11].

Trichomegaly

Trichomegaly refers to abnormally long eyelashes. This is associated with a number of congenital and acquired conditions and may result in secondary eyelid and lash ptosis. Trichomegaly was first reported by Gray in 1944 to describe a patient with lymphoma who had unusually long lashes [12]. Children with allergic eye disease (vernal keratoconjunctivitis) are found also to have longer lashes, particularly of the upper lid [13]. Certain medications, in-particular topical prostaglandin analogues used in glaucoma treatment including bimatoprost [14], latanaprost [15] and travoprost [16] are now well known to cause trichomegaly, as well as affect melanocyte turnover in the eyelash follicles [17]. Trichomegaly can result in build-up of the eyelash microbiome and contribute to blepharitis as we will discuss further.

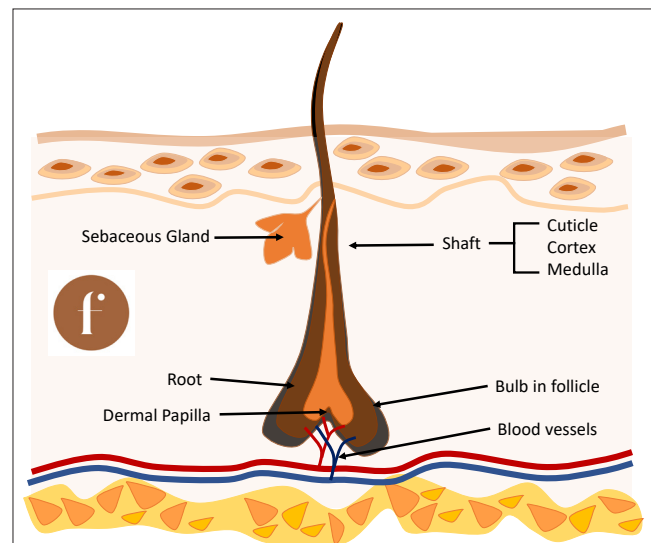


Figure 1: Anatomy of the eyelash. Cross section of an eyelash follicle. The shaft emerges through the skin coated with sebum from the sebaceous gland (gland of Zeis). A blood supply to the follicle supports growth.

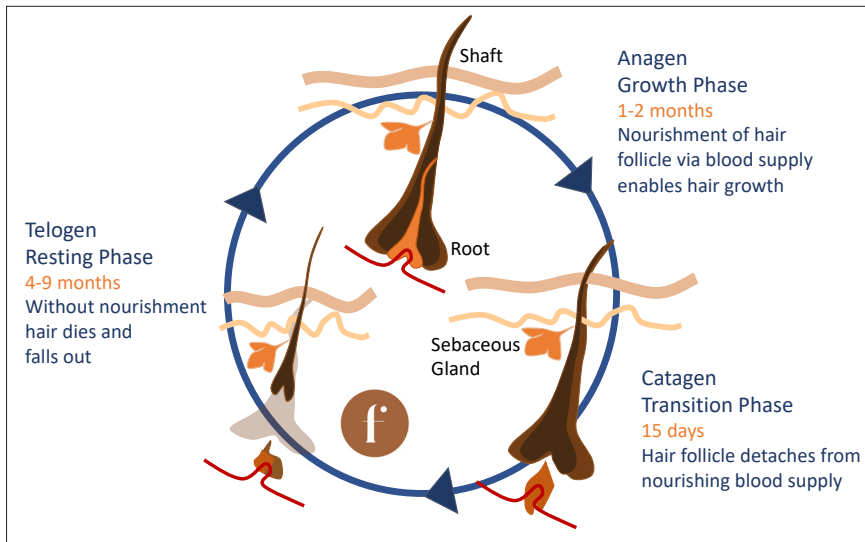


Figure 2: Eyelash lifecycle. All eyelashes go through a cycle of growth, transition and resting culminating in the loss of the blood supply and loss of the hair encouraged by a new hair pushing from below. Eyelashes have a short anagen phase and long telogen, resulting in short hairs of around 10mm and complete replacement of the eyelashes every six months or so.

Loss of eyelashes

Missing eyelashes (madarosis) can suggest serious pathology. When it is drastic and occurs as part of alopecia areata it is a significant emotionally traumatic event [18]. The loss of a few lashes may, however, go unnoticed but cannot be ignored by healthcare professionals as it can indicate systemic disease that is potentially life-threatening: madarosis can result from self-harm such as trichotillomania [19], or be a sequelae of trauma, chemotherapy, scleroderma, discoid lupus and hypothyroidism. Infectious causes include herpes zoster, leprosy, staphylococcus, HIV / AIDS and trachoma [20]. Critically eyelid growths that are malignant are more likely to destroy eyelash follicles and cause lash loss than benign growths and this should alert the clinician to refer onwards for management. Tumours can form from any of the structures in the eyelid and include basal cell carcinoma, squamous cell carcinoma, sebaceous carcinoma, Merkel cell carcinoma, melanoma and adenocarcinoma. A review of each is beyond the scope of this paper but all require dedicated expert referral. However, one subtle sign that should prompt referral and hence worth mentioning is that of unilateral blepharitis. Blepharitis is invariably a bilateral condition except when secondary to unilateral drop instillation and a reaction of the lid to the preservatives found in most eye medication. In any other scenario of apparent unilateral blepharitis, sebaceous carcinoma must be excluded. Though rare, these are highly malignant tumours [21].

Eyelash related lesions

Fortunately, the majority of growths near the lashes are benign. They can originate from any of the glandular tissue associated

with the eyelashes and are most often due to plugging and inflammation of the glands called blepharitis. This is a significant cause of later chronic DED, hence early recognition and management can help to reduce late morbidity [22]. Styes (infected hair follicles), chalazia (infected or blocked meibomian glands), cysts of Moll (blocked sweat glands or hygrocystomas) and cysts of Zeis (blocked sebaceous glands) may all present with a similar appearance and can co-exist [23]. Blepharitis and lid cysts from meibomian gland dysfunction (MGD) are more common in fair-skinned Scandinavian and Caucasian individuals, where there is a higher incidence of acne rosacea [24], but can occur in all races and age groups from childhood onwards. Patients often cite numerous factors as contributory, including stress, lack of sleep, dehydration, extended visual display unit (VDU) use, and currently, with the use of personal protective equipment (PPE) and fogging of spectacles and goggles. MGD affects 96% of glaucoma patients on prostaglandin analogues [25], nearly 60% of contact lens wearers [26] and 85% who work long-term with VDUs and digital devices [27]. In patients with concomitant blepharitis and MGD with an acute hordoleum, warm compresses aiming for a temperature of 45°C (113°F) at the outer lid surface [28], vertical massage towards the lashes and eyelid hygiene with blepharo-exfoliation at home or in-office, usually results in resolution. Chalazia are less likely to resolve if of duration longer than two months, early intervention is therefore important [29]. Topical antibiotic, either alone or with topical steroid is sometimes useful, but is of no greater advantage than massage alone and can result in bacterial resistance if used long-term. Apocrine eyelid cysts do not cause

lash loss as they are not destructive, and so some practitioners are happy to lance them at the slit-lamp. However, caution is warranted as a number of malignant lesions can masquerade as cysts, including cystic basal cell carcinoma, adenocarcinoma and sebaceous carcinoma. We feel all should be adequately excised and biopsied, not simply lanced, as there is a risk of missing malignancy without histopathology, particularly with recurrent lesions [30].

A number of eyelash follicle abnormalities can also form lumps or protrusions and are almost always benign. These include Trichoepithelioma, Trichofolliculoma, Trichilemmoma and Piloatrixoma [31]. Of course, like other hairs, eyelashes can also be in-growing, never protruding from the skin surface and thereby cause swellings [32].

Blepharitis and Demodex

The skin of the periocular area, the eyelid margin and less so the conjunctival lining of the eye is populated by a host of normal commensal bacteria, most commonly coagulase-negative staphylococcus and *S. aureus* [33].

The purpose of this microbiome is not yet clear, although microbiomes elsewhere such as in the gut and nasal cavity may play a role in immune mediated ocular pathology such as thyroid eye disease [34]. Ocular microbiome imbalances are implicated in blepharitis and DED, which can be debilitating with ocular burning, irritation and foreign body sensation. Hypersensitivity to Staphylococcal exotoxins is a common cause of blepharitis resulting in lid margin inflammation and crusts that plug the meibomian gland orifices. This in turn interferes with the normal supply of oil secretions to the ocular surface, resulting in an unstable tear film and DED. To compensate, the eye waters, causing further debilitation due to visual fluctuation. A vicious cycle then ensues with further gland stasis and bacterial biofilm perpetuating the inflammation.

Maintaining lid hygiene and massage is paramount but can be difficult to achieve. Eyelid and eye specific cleansing products can help. Purifeyes by FaceRestoration™ (pure hypochlorous solution, CHT Ltd) has the advantage of being an effective antimicrobial specific for ocular and periocular use without causing bacterial resistance. Other solutions that aid eyelid hygiene are Blephaclean™ (micellar solution, SpectrumThea) or OcuSoft™ Lid Scrub (modified Ringer's solution with preservative). Traditionally baby shampoo was recommended as a treatment option for eyelid hygiene, many however contain the preservative formaldehyde. This can

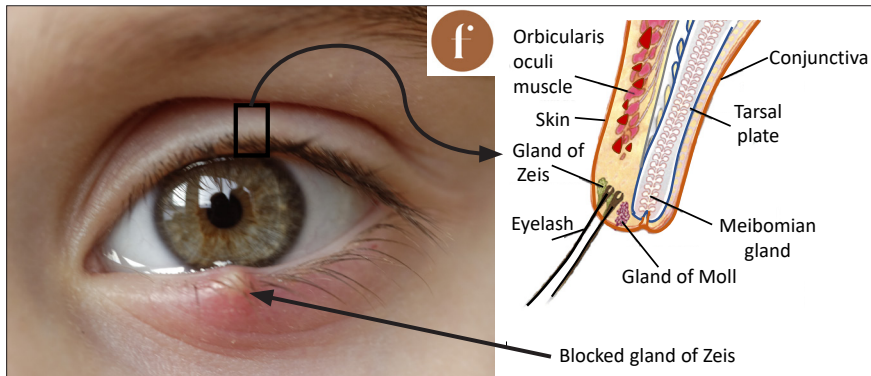


Figure 3: Eyelid anatomy. Eyelid with inset showing sagittal anatomy and position of lash follicles and surrounding glands. The lower lid shows a cyst of Zeiss. The glands maintain and support the tear film and ensure a protected and moist lid margin. Modified sweat glands (glands of Moll) secrete antimicrobial components. Tarsal (Meibomian) glands are hormone sensitive, modified sebaceous glands that produce the lipid layer of the tear film and pheromones. With age these glands atrophy and contribute to dry eyes.

be counter-productive and aggravate blepharitis and so should be avoided.

Eye makeup and lash extension glues also often contain formaldehyde which can predispose to and worsen biofilm and allow colonisation by the lash mite *Demodex*. The presence of small crusty cylinders around the lash base called collarettes can suggest the presence of these mites. Their prevalence increases with age, and though they can be found in around 25% of asymptomatic controls, they are present in over 63% of blepharitis patients, especially those who experience itching [35]. Oil based makeup is also an excellent breeding ground for *Demodex* and patients should be advised about lid hygiene and make-up habits.

As alluded to earlier – blepharitis is invariably bilateral and so unilateral crusting requires further investigation.

Trichiasis and distichiasis

Misdirected lashes (trichiasis) can cause blindness. The most common cause in the developing world is *Chlamydia trachomatis*, which has been subject to a sustained effort at control by the World Health Organization (WHO). Trachoma causes scarring on the conjunctival surface (see Figure 3), which draws the lashes in towards the eyeball, causing rubbing against the clear corneal surface and eventual scarring and opacity. This is best treated with a combination of antibiotic eradication and surgical correction. Elsewhere, misdirected lashes result most commonly from blepharitis but also local or systemic conjunctival scarring disorders, such as ocular cicatricial pemphigoid and Stevens-Johnson syndrome. Distichiasis is a condition where lashes also rub against the eye, but unlike trichiasis, the lashes originate from the wrong place. This can be from the conjunctival surface or from meibomian glands being transformed from chronic inflammation. Misdirected lashes have a high rate of recurrence even with the latest surgical procedures.

Mis-coloured eyelashes

Canities is the natural gradual greying of lashes due to a decrease in tyrosine production in the lash bulb. Poliosis is the abnormal loss of colour of lashes due to abnormality of melanocytes. This can be incidental but more usually is a marker of staphylococcal infestation or viral disease such as herpes zoster on the lids. It can also be caused by vitiligo, topical prostaglandin analogs, sarcoidosis [36] and a rare but serious cause, Vogt Koyanagi Harada syndrome, which affects multiple systems including the eyes, ears, nervous system and skin due to chronic inflammation of melanocytes [37].

Enhancing eyelashes

The side-effects of darker, thicker and longer lashes in glaucoma patients on 0.03% Bimatoprost led to a repurposing; in 2008 Latisse™ (bimatoprost 0.03%, Allergan) was first approved by the FDA for use in hypotrichosis. Daily application targets the anagen phase of the eyelash growth cycle. Many over the counter eyelash serums have since risen in popularity in the cosmetic industry, available without prescription, and not required to list potential side-effects. These will often contain synthetic

prostaglandins that can be difficult to spot unless you are familiar with the common names. The key is to look out for 'prost' in the ingredient list as an indicator of a potential synthetic prostaglandin. These will have the same potential side-effects as bimatoprost including blepharitis, without the monitoring that would occur with a prescribed drop, and should be avoided in patients with chronic ocular inflammatory conditions and DED [38]. Bimatoprost can also result in atrophy of the periorbital adipose tissue, usually over four months of use, creating a deep hollow around the eyes and deeper superior sulcus [34]. This area can be treated non-surgically with hyaluronic acid fillers but it is a high-risk area for vision loss being close to anastomoses connecting branches of the external carotid and ophthalmic artery and direct branches of the ophthalmic artery supplying the retinal circulation. This area should be treated with extreme caution and by those experienced in the technique as well as able to manage any potential complications [39].

False eyelashes

Traditionally false lashes are either synthetic nylon, silk or made from natural hair and then glued at the lid margin above the existing lashes with glues that often contain harsh ingredients with allergenic properties, including formaldehyde and latex. The predominant component of eyelash glue is ethyl cyanoacrylate. Numerous reports of allergy and burns to the eye have been reported [40]. More recently some false lashes have been made to attach magnetically, either small magnets sandwich a patient's real lashes between a set of upper and lower false lashes or the magnetic false lashes attach above the lash line to a thick line of metallic based eyeliner – something to be aware of before putting someone in an MRI machine [41]!

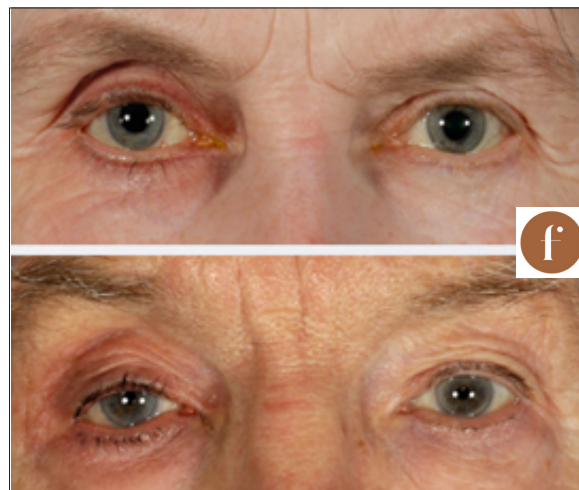


Figure 4: Bimatoprost and deepening superior sulcus. Two patients treated with bimatoprost for glaucoma to their right eyes only. The superior sulcus is seen to be hollowed and the lid margin more pigmented and darker. The extra lid show gives a tired aesthetic look. The lashes are also more prominent compared to the untreated left eyes. Even three years after cessation of treatment the fat atrophy persisted. This gave Dr Murthy the original idea to trial the drug for conditions where there is excess adipose tissue such as in thyroid eye disease [34].

COVID-19 and implications for professionals working near the eyes

Eyelash pathology can result in ocular hyperaemia, which is an indication of inflammation of the eye and blepharo-conjunctivitis, which if of viral origin can be contagious.

At the time of writing this article COVID-19 has been confirmed as a cause of conjunctivitis and viral RNA can be found in tears [42]. It is also recognised that any upper respiratory tract infection may result in viral conjunctivitis as a secondary complication. This also appears to be the case with COVID-19 [43].

Although conjunctivitis is rarely the initial presentation of COVID-19, there is a potential risk of viral transmission from contact with the tear film, ocular surface and skin that has been in contact with tears [44]. However, asymptomatic COVID-19 patients will more often have white eyes with no evidence of conjunctivitis.

Current guidance recommends that for all patients attending healthcare facilities, scrupulous infection control and hand hygiene measures are employed. Where possible, eye protection should be used by practitioners, and stringent asepsis of the skin including the periocular area is important. Critically, alcohol-based products used to sanitise hands must not be used near the eye as this can result in corneal de-epithelialisation, and commonly used skin antiseptics such as chlorhexidine are toxic to the cornea [45]. The empirical use of a safe non-alcohol based, anti-microbial ocular spray or drop, such as minims povidone iodine 5% w/v solution or non-stinging Purifeyes by FaceRestoration™, may reduce the risk of viral transmission and is an added safety measure where close proximity to the eyes is required [46].

References

- Yarbus AL. *Eye Movements and Vision*. Translated from Russian by Basil Haigh. Plenum Press: New York; 1967.
- Wikipedia. Eye liner: https://en.wikipedia.org/wiki/Eye_liner
- Eyelashes in history: http://eyelashesinhistory.com/ancient_times.html
- Ryerson JM, Perry HD. DEBS- a unification theory for dry eye and blepharitis. *Clin Ophthalmol* 2016;**10**:2455-67.
- Montagna W, Ford DM. Histology and cytochemistry of human skin 3. The eyelid. *Arch Dermatol* 1969;**100**:328-35.
- Halata Z, Munger BL. The sensory innervation of primate eyelid. *Anat Rec* 1980;**198**:657-70.
- Byun TH, Kim JT, Park HW, Kim WK. Timetable for upper eyelid development in staged human embryos and foetuses. *Anat Rec* 2011;**294**:789-96.
- Paus R, Burgoyne I, Griffiths T, et al. Biology of the eyelash hair follicle: and enigma in plain sight. *Br J Dermatol* 2016;**174**(4):741-52.
- Standing S. *Gray's Anatomy: The Anatomical Basis of Clinical Practice*. London, UK: Churchill Livingstone/Elsevier; 2008.
- Na JJ, Kwon OS, Kim BJ, et al. Ethnic characteristics of eyelashes: a comparative analysis in Asian and Caucasian females. *Br J Dermatol* 2006;**155**:1170-6.
- Dawber RPR. *Diseases of the Hair and Scalp*. Malden, MA: Blackwell Science; 1997.
- Paul LJ, Cohen PR, Kurzrock R. Eyelash trichomegaly: review of congenital, acquired, and drug-associated aetiologies for elongation of the eyelashes. *Int J Dermatol* 2012;**51**:631-46.
- Pucci N, Novembre E, Lombardi E, et al. Long eyelashes in a case series of 93 children with vernal keratoconjunctivitis. *Pediatrics* 2005;**115**(1):e86-e91.
- Hempstead N, Hempstead RW. Unilateral trichomegaly induced by bimatoprost ophthalmic solution. *J Drugs Dermatol* 2004;**3**:571-2.
- Woo TL, Francis IC. Intermittent blurred vision and trichomegaly due to latanoprost. *Clin Exp Ophthalmol* 2001;**29**:272-3.
- Li N, Chen XM, Zhou Y, et al. Travoprost compared with other prostaglandin analogues or timolol in patients with open-angle glaucoma or ocular hypertension: meta-analysis of randomised controlled trials. *Clin Exp Ophthalmol* 2006;**34**:755-64.
- Smith S, Fagien S, Whitcup SM, et al. Eyelash growth in subjects treated with bimatoprost: a multicentre, randomised, double-masked, vehicle-controlled, parallel group study. *J Am Acad Dermatol* 2012;**66**:801-6.
- Wang J, Lu Z, Au JL. Protection against chemotherapy-induced alopecia. *Pharm Res* 2006;**23**:2505-14.
- Slawinska M, Opalska A, Mehrholz D, et al. Videodermoscopy supports the diagnosis of eyelash trichotillomania. *J Eur Acad Dermatol Venereol* 2017;**31**(11):e477-8.
- Khong JJ, Casson RJ, Huilgol SC, Selva D. Madarosis. *Surv Ophthalmol* 2006;**51**(6):550-60.
- Deprez M, Uffer S. Clinicopathological Features of Eyelid Skin Tumors. A Retrospective Study of 5504 Cases and Review of Literature. *Am J Dermatopathol* 2009;**31**:256-62.
- Lemp MA, Crews LA, Bron AJ, et al. Distribution of aqueous-deficient and evaporative dry eye in a clinic-based patient cohort: a retrospective study. *Cornea* 2012;**31**(5):472-8.
- Baek SH, Chi MJ. Clinical analysis of benign eyelid and conjunctival tumors. *Ophthalmologica* 2006;**220**:43-51.
- Carsten SM, Holmgren HR, Hult-Nyström T. Rosacea: a Clinical Review. *Dermatol Reports* 2016;**8**(1):6387.
- Mocan MC, Uzunosmanoglu E, Kocabeyoglu S, et al. The association of chronic topical prostaglandin analog use with Meibomian gland dysfunction. *J Glaucoma* 2016;**25**(9):770-4.
- Machalinska A, Zakrzewska A, Adamek B, et al. Comparison of morphological and functional Meibomian gland characteristics between daily contact lens wearers and nonwearers. *Cornea* 2015;**34**(9):1098-104.
- Wu H. The severity of the dry eye conditions in visual display terminal workers. *PLoS One* 2014;**9**(8):e105575.
- Murakami DK, Blackie C, Korb D. All warm compresses are not equally efficacious. *Optom Vis Sci* 2015;**92**(9):e327-33.
- Wu AY, Gervasio KA, Gergoudis KN, et al. Conservative therapy for chalazia: is it really effective? *Acta Ophthalmol* 2018;**96**:e503-9.
- Roos J, Murthy R. Diagnostic accuracy of direct referrals for excision biopsy on non-consultant led minor operations lists. ESOPRS Presentation 2019 Hamburg. Page 13 https://www.esoprs.eu/wp-content/uploads/2019/08/ESOPRS_FINAL_PROGRAMME2019-090919.pdf
- Tao J, Yoon SJ. Lash Follicle, Tumors Arising in. In: Schmidt-Erfurth U, Kohnen T (eds). *Encyclopedia of Ophthalmology*. Springer: Berlin, Heidelberg; 2018.
- Dewan T, Sharma C, Chawla H, et al. Cilium incarnatum externum. *Digit J Ophthalmol* 2017;**23**(1):16-7.
- Barry P, Behrens-Baumann W, Pleyer U, Seal D. ESCRS Guidelines on prevention and management of post-operative endophthalmitis. 2007. http://www.esprs.org/vienna2011/programme/handouts/ic-100/ic-100_barry_handout.pdf
- Roos JCP, Murthy R. Update on the clinical assessment and management of thyroid eye disease. *Current Opin Ophthalmol* 2019;**30**(5):401-6.
- Biernat MM, Rusiecka-Ziółkowska J, Piątkowska E, et al. Occurrence of Demodex species in patients with blepharitis and in healthy individuals: a 10-year observational study. *Jpn J Ophthalmol* 2018;**62**(6):628-33.
- Lett KS, Deane JS. Eyelash poliosis in association with sarcoidosis. *Eye (Lond)* 2005;**19**(9):1015-7.
- Tabbara KF. Reversal of poliosis and vitiligo following Vogt-Koyanagi-Harada disease. *Arch Ophthalmol* 2012;**130**(3):394-6.
- Jones D. Enhanced eyelashes: prescription and over-the-counter options. *Aesthetic Plast Surg* 2011;**35**(1):116-21.
- Murthy R, Roos JCP, Goldberg RA. Periocular hyaluronic acid fillers: applications, implications, complications. *Curr Opin Ophthalmol* 2019;**30**(5):395-400.
- Nardeosingh S, See Wah Tung A. Thermal injury and false eyelashes. *Eye News* 2020;**26**(6):54-6.
- Slonimsky E, Mamourian A. Magnetic Eyelashes: A New Source of MRI Artifacts. *AJR Am J Roentgenol* 2019;**213**(5):983-5.
- Seah IYJ, Anderson DE, Kang AEZ, et al. Assessing Viral Shedding and Infectivity of Tears in Coronavirus Disease 2019 (COVID-19) Patients. *Ophthalmology* 2020;**127**(7):977-9.
- Seah I, Agrawal R. Can the Coronavirus Disease 2019 (COVID-19) Affect the Eyes? A Review of Coronaviruses and Ocular Implications in Humans and Animals. *Ocul Immunol Inflamm* 2020;**28**(3):391-5. Yan A. Chinese expert who came down with Wuhan coronavirus after saying it was controllable thinks he was infected through his eyes. *South China Morning Post*, 2020: <https://www.scmp.com/news/china/article/3047394/chinese-expert-who-came-down-wuhan-coronavirus-after-saying-it-was>
- Scalinci S, Battagliola E. Conjunctivitis can also be the only presenting sign and symptom of COVID-19. *IDCases* 2020;**20**:e00774.
- Mac Rae SM, Brown B, Edelhauser HF. The Corneal Toxicity of Presurgical Skin Antiseptics. *Am J Ophthalmol* 1984;**97**(2):221-32.
- Edington M, Ramaesh K, Lockington D. Virucidal benefits of povidone-iodine use on the ocular surface: a review. *BMJ Open Ophthalmology* 2020;**5**(1):e000509.

(All links last accessed August 2020)

AUTHORS



Rachna Murthy,

Cambridge and London-based Consultant Oculoplastic Aesthetic & Reconstructive Surgeon; co-owner, FaceRestoration. Trained in Melbourne, Chelsea & Moorfields and sits on the RSM Ophthalmology Council and IMCAS Alert Board.



Jonathan CP Roos,

Harvard, Cambridge & Moorfields-trained Consultant Oculoplastic Surgeon and academic based in London at www.FaceRestoration.com. Publishes in the world's leading medical journals and lectures internationally on aesthetics, eyelid diseases and thyroid eyes.

Declaration of competing interests: The authors have developed in collaboration with CHT Ltd a skin cleansing product – *Purifeyes by Face Restoration™* and run a filler safety dissection course in Cambridge www.aesthetics-course.com